

THE EFFECT OF THE DRUG MIOSTA H® IN THE TREATMENT OF PURULENT AND NON-PURULENT INFLAMMATORY PROCESSES IN THE JOINTS OF THE LEGS IN HORSES

Niyazov Kh.B., Doctor of Veterinary Sciences, Professor
Samarkand State University of Veterinary Medicine, Animal Husbandry and Biotechnology

A.K. Ruziboev, assistant
Samarkand State University of Veterinary Medicine, Animal Husbandry and Biotechnology

Kh.H. Eshkuvatov, assistant
Samarkand State University of Veterinary Medicine, Animal Husbandry and Biotechnology

S.B. Abdiev, senior lecturer, (PhD)
Samarkand State University of Veterinary Medicine, Animal Husbandry and Biotechnology

B. Kokilov, assistant
Samarkand State University of Veterinary Medicine, Animal Husbandry and Biotechnology

A. Ruziev , basic doctoral student
Samarkand State University of Veterinary Medicine, Animal Husbandry and Biotechnology

Received: May 22, 2024; Accepted: Jun 10, 2024; Published: Jul 17, 2024;

Abstract: In this article, when treating horses with a purulent coffin joint, surgical treatment is performed, enrofloxacin 10% is injected into the muscle, platelet autoserum is injected around the joint, chondrolone is injected into the joint, and Miosta H® is injected into the muscle, and the wound is treated with levomekol ointment. On the 18-19th day, horses normally experience early formation of scabs, lameness, swelling and a local decrease in leg and body temperature, and when treating horses with chronic non-purulent diseases of the joints of the feet, a sharp tickling ointment is used, massage and paraffin applications are applied around the joint and hydrocortisone 0.5% novocaine. It was also reported that with intramuscular injection of 5 ml of Miosta H® for the first time and 10 days after intra-articular injection of 5 ml of chondrolone, lameness, swelling and local temperature decreased, and body temperature in horses normalized by day 14.

Keywords: Purulent synovitis of equine joints, capsular phlegmon, purulent arthritis, platelet autoserum, enrofloxacin, chondrolone, levomekol, non-purulent synovitis, acute ticklish ointment, massage, paraffin baths and hydrocortisone, novocaine, Miosta H®.



This is an open-access article under the [CC-BY 4.0](https://creativecommons.org/licenses/by/4.0/) license

Introduction

Relevance of the topic. Joint pathologies are more common in horses involved in sports and sport, mainly in late autumn, winter and spring, and in 51 horses out of 295 (17.3%) farms of the republic, various non-purulent inflammations of the joints were observed. Of these, 11 had acute synovitis, 18 had chronic synovitis at the head of the horse and periarticular fibrositic processes in 22 heads of animals are the main causes of greater damage to the joints of the legs in horses participating in the lot [5,6].

Chronic periarticular fibrosis of the joints, caused by various types of trauma and repeated trauma in horses, is characterized by joint disfigurement, an increase in the fibrous capsule, thickening of the joint ligaments, decreased elasticity, severe pain when the animal moves, and unilateral damage to the joints. heel, wrist and hip joints [7].

Synovial fluid in the joints of horses affected by chronic periarticular fibrositis, a colorless, transparent, mucinous mixture in the form of a large and transparent mass, viscosity 4.5-5.5 cm, an increase in lymphocytes and monocytes and a decrease in leukocytes, and neutrophils are noted in the synoviocytogram, due to thickening of the layer, overgrowth of connective tissue between the periarticular tissue and articular ligaments, their hardening and loss of elasticity are observed [8].

In the treatment of chronic non-purulent inflammation of the joints in horses, in addition to generally accepted methods, intra-articular administration of 0.5 ml/kg body weight of autologous blood irradiated with neon-helium laser light and 2 ml of chondrolone intra-articularly reduces the duration of treatment - 5-6 days, while the number of red blood cells in the blood - on average by 9.5%, the number of leukocytes - by 25.3%, the amount of hemoglobin - by 22.5%, the relative indicator of lymphocytes - by 10%, the amount of total protein by 19.7%, gamma globulins by 11.2%, beta globulins by 31.8%, relative number of T-lymphocytes by 4.9%, absolute number by 30%, relative number of B-lymphocytes by 16%, absolute number by 50% and A-, M - and G-immunoglobulins, respectively, provides an increase of 61.5%, 10% and 14.2% [9,10].

Treatment with the patient's own blood, that is, in addition to autohemotherapy, includes methods of using various fractions for therapeutic purposes: erythrocyte mass [3], leukocyte plasma [2] and platelet-rich plasma. Platelet-rich plasma is centrifuged twice and the activator calcium chloride is added to the test tube, the concentration of platelets in it reaches 1,000,000/ μ l, and according to some data - 970-1574 thousand/ml [4].

Annikov V.V. and others [1] obtained positive results in the treatment of aseptic osteoarthritis in dogs with platelet-rich plasma.

In global veterinary practice, extensive scientific research is being carried out on the production of biostimulants, studying their pharmacological effects on the animal body, and assessing the quality of products for consumption from the point of view of veterinary hygiene. In global veterinary practice, extensive scientific research is being carried out on the production of biostimulants, studying their pharmacological effects on the animal body, and assessing the quality of products for consumption from the point of view of veterinary hygiene.

Purpose of the study. Taking into account the above, the goal was to determine the effectiveness of the drug Miosta H®, produced in our country, in the treatment of purulent and non-purulent inflammation of the ankle joints in breeding farms and sports horses under the care of the population

Methods

Our treatment studies were carried out in the vivarium of the Department of Veterinary Surgery and Obstetrics of the Samarkand State University of Veterinary Medicine, Animal Husbandry and Biotechnology on horses with purulent and non-purulent diseases of the joints of horses of horse breeding farms belonging to the population of Jizzakh, Kashkadarya, Navoi, Bukhara and Samarkand regions of our Republic.

At the first stage of the experiments, using general and special examination methods, 6 horses with purulent-inflammatory processes in the ankle joint were identified and 3 heads were divided into 2 groups - control and experimental.

Conventional methods were used to treat joint inflammation. During surgery, premedication and local anesthesia were administered. To do this, the area around the inflamed joints was opened, cleared of pus and washed with 3% H₂O₂, enrofloxacin 10% 6 ml between the muscles, platelet autoserum 4 ml 1 time in 3 days around the wound, after the cessation of pus, chondrolone 4 ml and Levomekol ointment were used intra-articularly.

In addition to generally accepted methods, the animals of the first experimental group were administered the drug Miosta H® 5 ml intramuscularly in the neck area for the first time after the cessation of pus discharge and a second time 5 ml intramuscularly in the neck area after 10 days.

At the second stage of the experiments, using general and special examination methods, 6 horses with an aseptic inflammatory process in the ankle joint were identified. The sick animals were divided into two groups of 3 heads each into control and experimental groups according to the principle of similar pairs.

For the treatment of non-purulent inflammation of the joints in horses of the second control group, reduction of proliferative and fibroplastic processes in chronic non-purulent inflammation of the joints, improvement of lymph and blood circulation, resorption of proliferates and softening of connective tissues, traditional methods are used; horses of the second control group were treated with 0.5% novocaine around the joint 3 times every 48 hours, and chondrolone was applied intra-articularly 3 times every 48 hours.

In the first experimental group, in addition to the generally accepted methods, the drug Miosta H® was used the first time, 5 ml between the neck muscles, and the second time after 10 days, 5 ml between the neck muscles

Result and Discussion

In the experiments of the first stage, the inflamed joints of horses of the second control group were opened, cleared of pus and washed with 3% H₂O₂, 10% enrofloxacin 6 ml intramuscularly, platelet autoserum 4 ml once every 3 days around the wound, after the release of pus stopped, chondrolone 4 ml was applied intraoperatively intra-articularly and Levomekol ointment. By the 5th day of treatment, horses experience purulent discharge from the joints, partial loss of appetite and increased body temperature, lameness in the legs, standing on the ground and the tips of the hooves in some of them, decreased mobility, swelling in the joints and local temperature. On the 6-7th day of treatment, swelling, local temperature and redness of the skin persisted in the joints, and lameness appeared when the animal moved. On the 12th day of the experiment, inflammation decreased somewhat, swelling of the joints decreased, elasticity was slightly restored, and the skin became smaller. Horses apply pressure to the tip of the hoof with the joints of the injured legs slightly bent. The support sags when the animals move. By the 10th day of the experiment, the horse stopped releasing pus from the joints, the body temperature decreased, lameness in the legs decreased, swelling of the joints and local temperature decreased. From the 17th day of treatment, during a clinical examination of infected animals, it was noted that the pathological defect was dry, the wound was covered with young granulation tissue, the skin around the joints was significantly reduced, and the swelling around the joints decreased. The elasticity of the fingers was significantly restored and the function of the fingers was restored.

On the 20-21st day of such treatment, it was noted that the horses' mobility was active, there was no lameness, swelling, local temperature, scars, the horses' body temperature was normal.

The drug Miosta H® was taken (A) by animals of the first experimental group with a purulent-inflammatory process of the palmar joint.

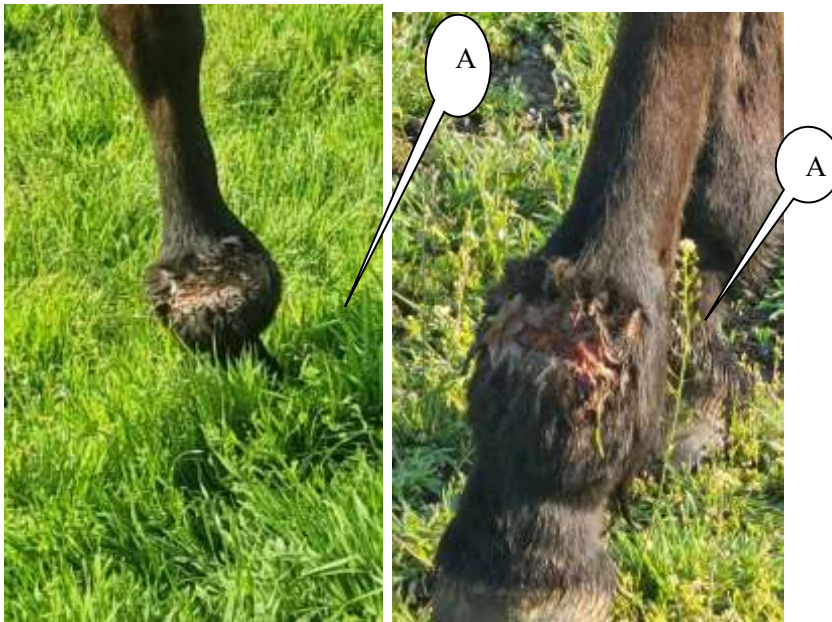

Figure 1. Day 5 of the experiment. Figure 2. 10th day of experiment.

When treating the first experimental group, the horses' joints were subjected to surgical treatment, the wound was cleaned with H₂O₂, enrofloxacin 10% - 6 ml intramuscularly, platelet autoserum 4 ml intra-articularly once every 3 days, and Levomekol ointment was administered. After the pus drained, 2 ml of chondrolone was injected into the joint, 5 ml of **Miosta H®** was injected into the neck muscle, and 10 days later a second time - 5 ml between the neck muscle joints. By the 5th day of treatment, severe pain in the joints of horses, partial loss of appetite and increased body temperature, lameness in parts of the legs, decreased mobility, swelling and local temperature were observed. By the 7th day of the experiment, the discharge of pus from the joints of the horses stopped, body temperature decreased, lameness in the legs decreased, swelling of the joints and local temperature decreased.

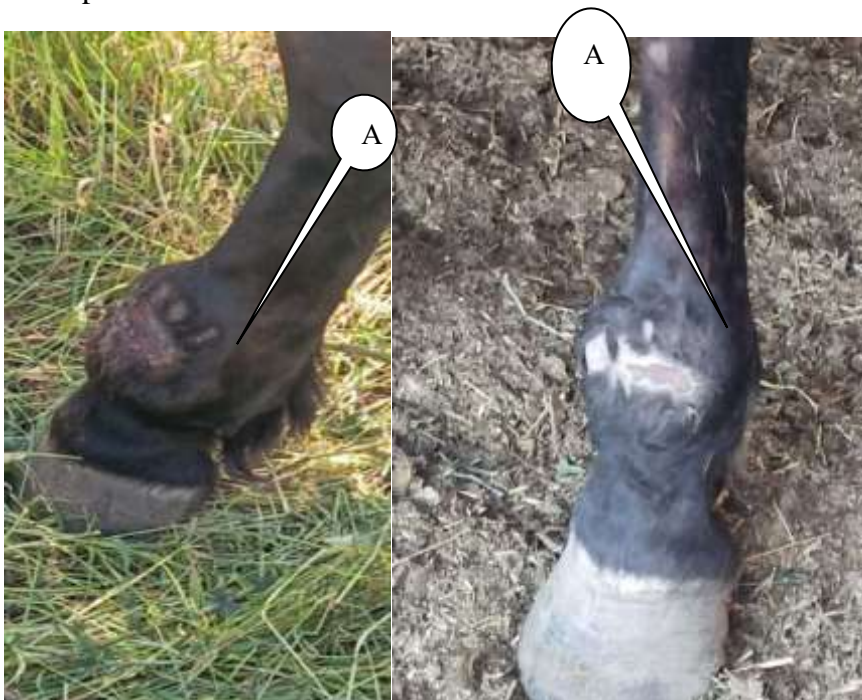

Figure 3. Day 15 of the experiment. Figure 4. Day 19 of the experiment.

The first experimental group of animals with purulent inflammation of the knee joint received the drug Miosta H® (A).

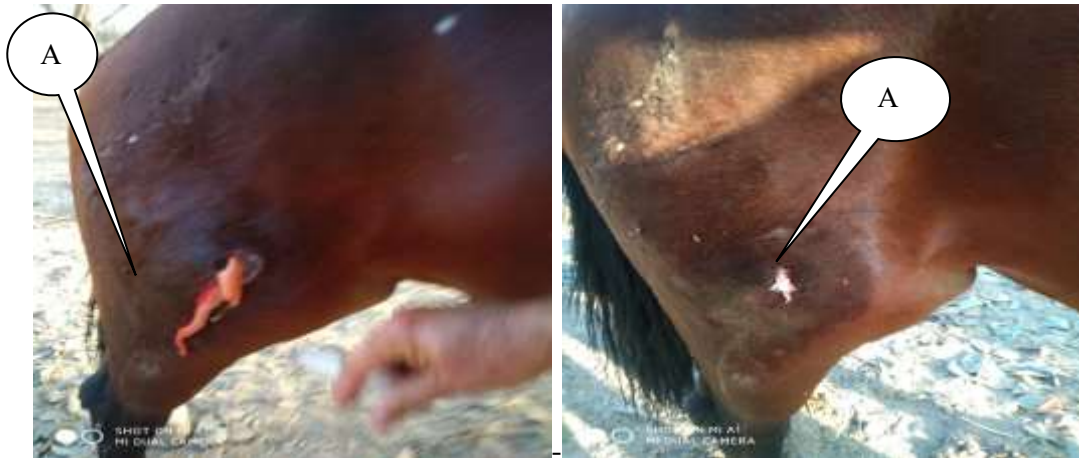

Figure 5. Day 5 of the experiment. Figure 6. Day 10 of the experiment.

From the 15th day of treatment, clinical examination of infected animals noted that the pathological defect was dry, the wound was covered with young granulation tissue, the skin around the joints was significantly reduced, the swelling around it was reduced, the elasticity of the fingers was significantly restored, and the function of the fingers was restored. The skin and hair of horses are light, shiny, normal skin is noted, growth and development of hair is good (Figures 1-7).



Figure 7. Day 19 of the experiment. Figure 8. Procedure for administering Miosta H®.

With this method of treatment, on the 18-19th day the horses were cured, their mobility was active, there was no lameness, swelling and local temperature in the legs, small scars were formed compared to the 2nd group and the body temperature of the horses was normal.

According to research results and the opinion of most authors, under the influence of biostimulants, the trophic function of the nervous system, adrenal glands, and pancreatic function improves. The level of adrenocorticotrophic and corticosteroid hormones increases, the functions of the secretory and motor gastrointestinal, reticuloendothelial (RES) systems, regenerative processes, respiration, cardiac activity, blood counts, wound fluid environment (pH) are normalized, early healing occurs, pain symptoms decrease, titer increases agglutinins and complement fixers in blood serum. The function of enzymes is restored, the general condition and appetite of the animal increases.

In the second stage of the experiments, horses of the second control group were given traditional methods of treating non-purulent joint inflammation, chronic non-purulent joint

inflammation, reducing proliferative and fibroplastic processes, improving lymph and blood circulation, absorption, proliferation and softening of connective tissues, i.e. ointment for acute tickling, massage, paraffin applications and hydrocortisone 4 ml + 0.5% novocaine 5 ml around the joint 3 times in 48 hours and chondrolone 4 ml intra-articularly 3 times in 48 hours.

On the 3rd day of treatment, animals feel severe pain upon palpation and passive movement of the joints. The joint capsule is tense and thickened. When palpating the articular diverticula and the capsule wall, a characteristic crunching sound is heard. When the animal is at rest, it often changes damaged legs, and lameness is noted when moving. The synovial folds of the joint are enlarged, upon palpation fluid is found in them, the maximum amount of fluid is observed on the 6-7th day of treatment, and strong fluctuation is noted. Accumulation of fibrin in the injured joint was observed until the 7th day, and in subsequent days its amount decreased.

From the 12th day of treatment, a clinical examination of animals with chronic fibrinous synovitis revealed that there was practically no swelling around the joint; upon palpation of the joint capsule, its elasticity was significantly restored and the function of the joint was restored. In animals with chronic fibrinous synovitis of this group, by the 16th day of treatment, the function and structure of the joints were restored to normal levels.

To treat non-purulent inflammation of the ankle joint in the first experimental group, traditional methods are used: sharp tickling ointment, massage, paraffin baths and hydrocortisone 4 ml + 0.5% novocaine 5 ml around the joint every 48 hours 3 times in 48 hours, 4 ml in total joint chondrolone only 3 times every 48 hours, and additionally 5 ml of **Miosta H®** were injected into the neck muscle for the first time and 5 ml between the neck muscles for the second time after 10 days.

On the 2-3rd day of treatment, the pain in the injured joint intensified and its size increased. The synovial folds of the joint are enlarged, upon palpation fluid is detected in them, the joint capsule is thickened and tense. In the joints of animals, deformation, swelling and tension of articular diverticula were observed. Sick animals exhibited a high degree of lameness and a severe pain reaction during passive movement.

On the 6th day of treatment, during the pathological process in the joints, the maximum amount of fluid and accumulation of fibrin was noted; upon palpation of the joints, creaking and fluctuation were detected. A decrease in the inflammatory process in the affected joints was detected on the 7th day of treatment. The joint capsule loosened a little, the synovial folds became smaller, and the amount of fibrin began to decrease. When moving the animals, it was noted that lameness decreased somewhat, the joints became free and less painful during passive movement.

From the 10th day of treatment, the swelling decreased and the elasticity of the skin began to restore; upon palpation of the articular capsule, diverticula and ligaments, the joint capsule was thickened, although the elasticity of the ligaments was not at the same level, it was thickened and no scars were observed. No crepitus was observed in the diverticula of the joint capsule.

From the 14th day of treatment, positive changes were observed in the clinical signs of the affected joints in animals of the second experimental group with this diagnosis; when palpating the joints, no swelling was noted, the elasticity of the skin was restored, and it was found that the function of the joints was restored to the level of healthy joints. The horses' body skin and coat are light, shiny, normal skin is noted, growth and development of the coat is good (Figures 9-14).

The first experimental group of animals with non-purulent inflammation of the palmar joint, receiving the drug Miosta H®.




Figure 9. Day 3 of the experiment. Figure 10. Day 10 of the experiment.

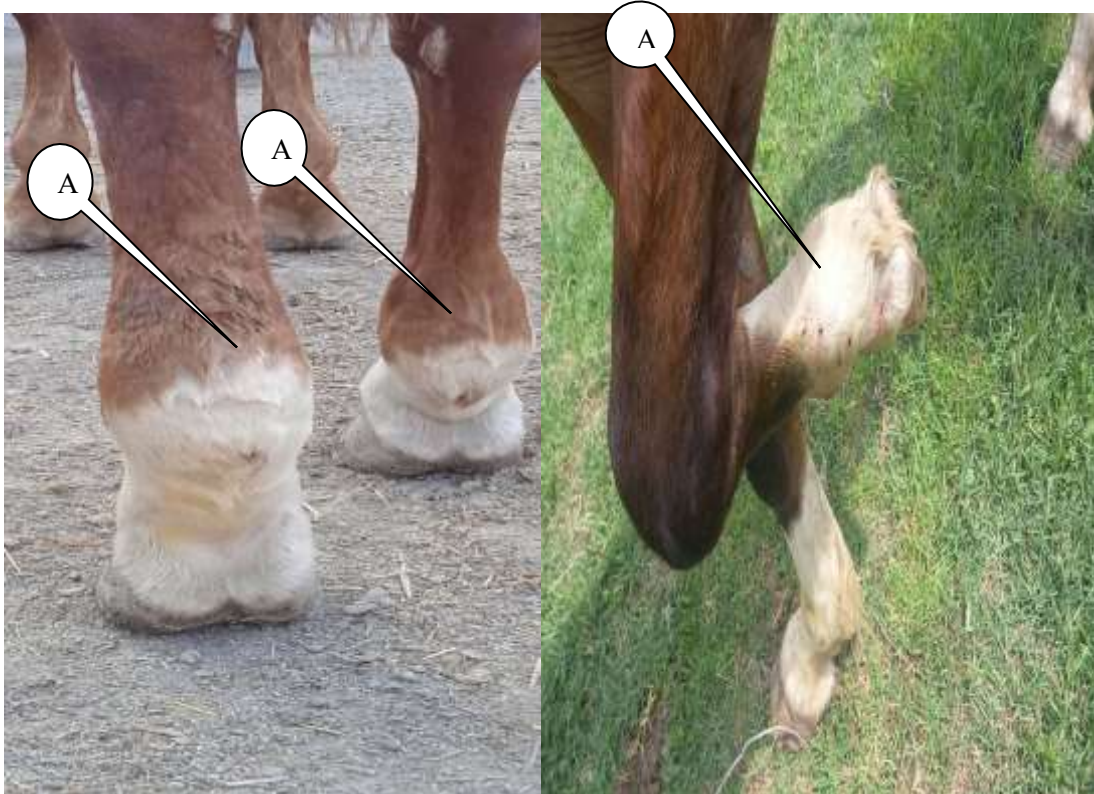


Figure 11. Day 14 of the experiment. Figure 12. Day 3 of the experiment.

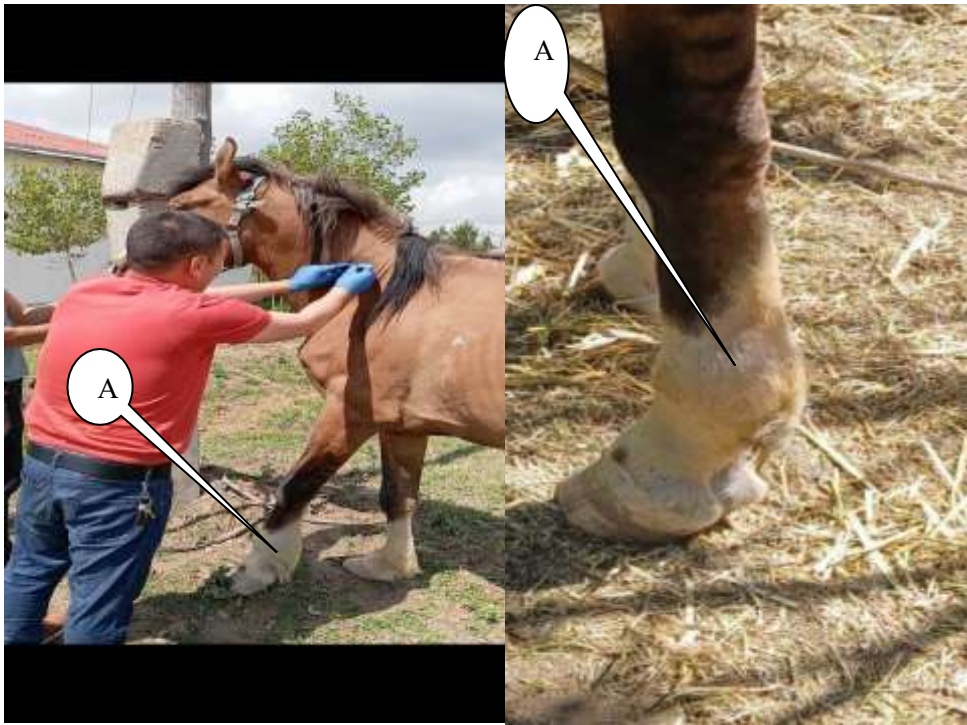

Figure 13. Day 10 of the experiment. Figure 14. Day 14 of the experiment.

Based on the data obtained from experiments, we can conclude that the treatment of chronic aseptic inflammation of the joints is aimed primarily at reducing proliferative, fibrinoplastic processes, tissue softening and extensive scarring; in the treatment of this pathology, various methods and means are used to normalize inflammation and improve blood - and lymph circulation, destruction of connective tissue, causing proliferative inflammation and scar formation.

Thus, the mechanism of the biological and therapeutic effects of heat on the animal's body is based on a kind of tickling of a large number of receptors located on the skin, in which pain decreases as the inflammatory process subsides, and inflammatory infiltrates are resolved. An increase in regenerative processes is observed, scars are resolved, and the restorative processes of the phagocytic reaction are activated.

In the treatment of chronic aseptic arthritis, the use of biostimulants also occupies one of the main places; under the influence of biostimulants, the trophic function of the nervous system, adrenal glands, and pancreas is improved, blood and lymph circulation is enhanced, fibrin resorption is accelerated, the proliferation and enlargement of connective tissue is achieved, scars are softened, and pain metabolism is reduced. In tissues, muscle tone increases, ligament elasticity increases, trophism is restored in the pathological area

Conclusion

1. In the treatment of horses with purulent inflammation of the hoof joints, an operation was performed and the wound was cleaned with H₂O₂, 10% enrofloxacin was injected into the muscle, platelet autoserum was injected around the joint, chondrolon was injected into the joint, Miosta H® was injected into the muscle, and levomekol ointment was applied to the wound. On the 18th and 19th days, early wound healing was observed, lameness, edema, and local temperature decreased, and the body temperature was normal.
2. When treating horses with chronic non-purulent joint diseases, acute tickling ointment, massage, paraffin applications and hydrocortisone 4 ml + 0.5% novocaine 5 ml around the

joint every 48 hours only 3 times are used, as well as chondrolone 4 ml intravenously injected into the joint a total of 3 times every 48 hours and in addition to them, with the first injection intramuscularly, 5 ml of the drug Miosta H® and after 10 days for the second time, 5 ml intramuscularly and on the 14th day it was noted that lameness, swelling and local temperature in the legs decreased, body temperature returned to normal

References

- [1]. Анников В.В. Оценка эффективности PRP-технологии лечения животных с асептическими остеоартрозами / В. В. Анников, Ю. В. Пигарева, А. С. Рыхлов, Л. В. Анникова // Аграрный научный журнал. – 2013. - № 3.-С.3-6.
- [2]. Виноходов, В. В. Лейкоцитарная плазма. Препарат и его применение в свиноводстве: автореф. дис. ... д-ра вет. наук / В. В. Виноходов. - Харьков, 1972.-53 с.
- [3]. Грачев, А. Е. Влияние длительности хранения криоконсервированных эритроцитов на качество и эффективность трансфузий : автореф. дис. ... канд. мед.наук : 14.01.21 / Грачев Александр Евгеньевич. - М., 2013. - 25 с.
- [4]. Нахапетян, Т. Г. Экспериментально-морфологическое и клиническое обоснование применения обогащенной тромбоцитами аутоплазмы при хирургическом лечении разрывов ахиллова сухожилия : автореф. дис. ... канд.мед. наук / Т. Г. Нахапетян. - М., 2013. - 22 с.
- [5]. Ниёзов Х.Б., Давлатов Н.Ш., Жураев Д. Анализ заболеваемости и клинического проявления асептических болезней суставов у лошадей. // Зооветеринария. – Тошкент, 2012. - № 11. -Б.15-17.
- [6]. Ниёзов Х.Б., Давлатов Н.Ш., Жураев Д. Отлар оёқлари дистал бўғимларида сурункали асептик яллиғланишлар ва уларни даволаш. // Зооветеринария. – Тошкент, 2012. - № 4. -Б.14-16 .
- [7]. Ниёзов Х.Б., Жураев Д., Юлдошева М. Спорт отларнингда бўғимларнинг йирингсиз яллиғланишлари ва уларнинг этиопатогенези. // Ўзбекистон қишлоқ хўжалик журналининг Агро илм илмий иловаси. – Тошкент. 2012. -№2. - Б. 46-48.
- [8]. Ниёзов Х.Б., Жураев Д., Файзиев У. Отларнинг бўғим касалликларини даволаш. // Ўзбекистон қишлоқ хўжалиги. – Тошкент. 2012. - №9.- Б. 35-38.
- [9]. Ниёзов Х.Б., Жураев Д. Некоторые особенности этиопатогенеза гнойных артритов у спортивных лошадей. // Зооветеринария. – Тошкент, 2013. - №1. -Б.18-20.
- [10]. Niyozov H., Dilmurodov N., Davlatov N. Treatment of aseptic diseases of limb distal part joints in Uzbek sport horses. “Journal of Microbiology, Biotechnology and Food Sciences”, №12. 2016. P.478-481. Nitra. (Jurnal impact 0.29 INDEX COPER Nicus).
- [11]. Niyozov Kh.B, Davronov M.Kh, & Ruziyev A.I. (2021). TREATMENT OF SUPPURATIVE INFLAMMATION OF THE FINGER JOINT IN SPORT HORSES. Academicia Globe: Inderscience Research, 2(06), 355–359. <https://doi.org/10.17605/OSF.IO/R7W5G>
- [12]. A.I.Ruziyev, H.B.Niyozov, & A.G'.Jabbarov. (2024). QUYONLARDA YIRINGLI OTITLARNI DAVOLASHNI TAKOMILLASHTIRISH. Ustozlar Uchun, 1(1), 321–328. Retrieved from <https://pedagogs.uz/index.php/01/article/view/1693>