

Article

# Morphometric Analysis of the Mental Foramen in Libyan Population Using Cone-Beam Computed Tomography

Ashraf Elmansori<sup>1</sup>, Osama Othman Mohammed Ambarak<sup>2</sup>, Abdullatif H. Annaas<sup>3</sup>, Azza SH Greiw<sup>4</sup>, Randa Farag Salih<sup>5</sup>

- 1 Department of Anatomy, Faculty of Medicine, University of Benghazi, Benghazi-Libya
  - 2 Department of Anatomy, Faculty of Medicine, University of Benghazi, Benghazi-Libya
  - 3 Department of Anatomy, Faculty of Medicine, Omar Al-Mukhtar University, Al-Bayda- Libya
  - 4 Department of Family & Community Medicine, University of Benghazi, Benghazi- Libya
  - 5 PhD student, Tashkent Medical Academy
- \* Correspondence: [abdylatif.annaas@omu.edu.ly](mailto:abdylatif.annaas@omu.edu.ly)

## Abstract:

**Introduction:** The mental foramen is a significant anatomical landmark through which the mental nerve passes. The mental nerve is a branch of the inferior alveolar nerve that innervates the buccal vestibule anterior to the first mandibular molar, the lower lip, and the gums. There is evidence that race affects the location of the mental foramen. Thus, the purpose of this study was to collect data regarding the position and other relevant parameters of the mental foramen in the mandibles of the Libyan people.

**Material and method:** Cone beam computer tomography (CBCT) scans of 106 Libyan patients who attended the dental office (49 of them were men and 57 were women). Two calibrated examiners analyzed each scan. All the data underwent statistical analysis and results were obtained.

**Results:** Mental foramen was present bilaterally in all patients. The most common position of MF in our study was P3 (52.8%) 'below the 2nd premolar'. The next common position was P2 i.e., between the premolars (24.5%). The mean vertical diameters were  $3.15 \pm 0.78$  mm on the right and  $3.46 \pm 0.86$  mm on the left sides whereas the mean horizontal diameters were  $3.45 \pm 1.08$  mm and  $3.85 \pm 1.27$  mm on the right and left sides respectively. The average distance between MF and the alveolar margin of the mandible (Distance A) was  $13.77 \pm 2.42$  mm on the right side and  $13.57 \pm 2.21$  mm on the left side, with males slightly higher than females. While the distance between the MF and the lower border of the mandible (Distance B) was  $12.63 \pm 1.72$  mm on the right side and  $12.23 \pm 1.68$  mm on the left side, with males exhibiting a greater distance than females.

**Conclusion:** Understanding the morphometry of MF is very important. Therefore, our research may offer essential information about MF in the Libyan population, which may be helpful to anesthetists, neurosurgeons, and dental surgeons performing nerve blocks and surgical procedures such as periodontal, implant placement, or apical curettage of mandibular premolars.

**Keywords:** Mental foramen, Vertical diameter, Horizontal diameter, Mental nerve.

**Abbreviation:** MF (mental foramen); CBCT (cone-beam computed tomography); VD (vertical diameter); HD (horizontal diameter); SPSS (Statistical Package for Social Sciences).

**Citation:** Elmansori A., Ambarak O. O. M., Annaas A. H., Greiw A. S., Salih R. F. Morphometric Analysis of the Mental Foramen in Libyan Population Using Cone-Beam Computed Tomography. Scholastic: Journal of Natural and Medical Education 2024, 3, 7-16.

Received: 7<sup>th</sup> Jan 2023

Revised: 9<sup>th</sup> Jan 2023

Accepted: 18<sup>th</sup> Jan 2023

Published: 20<sup>th</sup> Feb 2024



Copyright: © 2024 by the authors. Submitted for possible open access publication under the terms and conditions of the Creative Commons Attribution (CC BY) license (<https://creativecommons.org/licenses/by/4.0/>).

## 1. Introduction

The mental foramen is present on the external surface of each side of the mandible. It transmits the mental nerve and vessels, mental nerve is a branch of the inferior alveolar nerve to supply the lower lip, gingiva, and also the buccal vestibule anterior to the first mandibular molar [1, 2]. The mental foramen marks the termination of the mandibular canal in the mandible, through which the inferior alveolar nerve and vessels pass. The mandibular canal bifurcates at this point to generate the incisive and mental canals [3]. The position of MF differs between genders and racial groups [4, 5]. The most common position of the MF is in line with the longitudinal axis of the 2nd pre-molar tooth followed by a location between the 1st and 2nd premolar teeth [6]. Studying position and its morphological variation of mental foramen is very important because it will be helpful to localize the important maxillofacial neurovascular bundle through the mental foramen. The mental foramen acts as an important anatomical landmark to facilitate the surgical, local anesthetic, and other invasive procedures for dental surgeons performing peri-apical surgery in the mental region of the mandible [7]. Numerous methods, including cadaveric dissection, computed tomography, periapical and panoramic radiography, magnetic resonance imaging, and cone-beam computed tomography (CBCT), have been used to determine the location of the MF [8]. The majority of these methods have disadvantages, including cost, radiation risk, and amplification. The most accurate and exact in vivo technique that offers an accurate and precise position of the MF prior to dental surgery is called the Cone beam computed tomography (CBCT) [9]. CBCT is a newer modality for dental and maxillofacial osseous diagnostic activities that replace traditional CT. Compared to a traditional CT scan, the CBCT, which was also utilized in this investigation, permits a quicker scanning duration and a reduced radiation dosage. With the help of the CBCT, precise pictures with submillimeter resolution can be obtained in formats that enable three-dimensional viewing of the maxillofacial region's intricacy [10]. This study used CBCT to measure the vertical and horizontal diameters as well as their distance from the mandibular borders and position of the mental foramen (MF) in relation to sex in a group of patients from Libya.

## 2. Materials and Methods

### 2.1. Study Design

All patients undergoing CBCT reconstruction in our dental office between January and October 2023 were retrospectively recruited for this study. The pre-operative clinical notes were reviewed to collect patient personal data and the reason for which the CBCT was requested. Patients between the ages of 18 and 65 years were included in the study. Exclusion criteria were patients with a history of previous surgery involving the posterior mandibular region, patients having maxillofacial deformity, or missing mandibular posterior teeth. Seven patients were also excluded due to incomplete or ambiguous documentation of the data. A total of 106 consecutive Libyan patients (57 women and 49 men) were included. Two independent reviewers, blinded to subjects' details, calculated

the vertical and horizontal diameters and additional parameters related to the MF, such as the distance from the MF to the alveolar crest and lower border of the mandible.

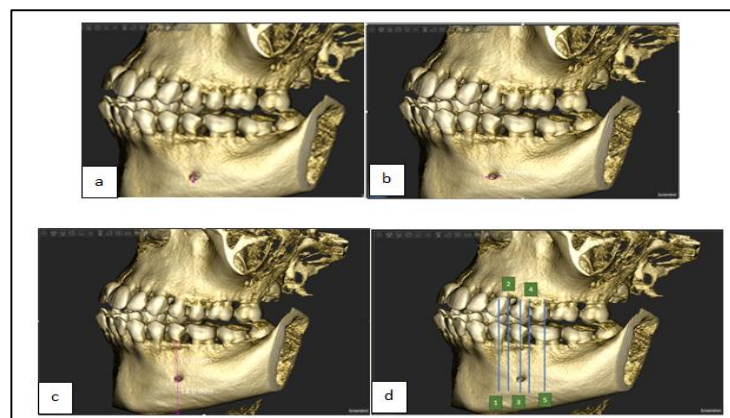
## 2.2. Radiographic Evaluation

The CBCT data were collected using Acteon XMIND CBCT (SOPRO Acteon group, France). The field of view was  $15 \times 12$  cm and the voxel size was 0.200 mm. Scans were performed at 84 kV and 12–16 mA. All images were analyzed using Acteon's AIS Software (Version 4.6.1.AIS) on a computer screen. All measurements were positioned as an overlay and remained in a fixed position on the complete image series.

For the MF area, all radiographical cuts panoramic, axial, coronal, and sagittal were employed for 3D construction of the interested area. The aim of this study was to evaluate the MF's location, horizontal and vertical diameters, and distance from the mandibular borders. Gender comparisons and the distinctions between the left and right sides were also assessed.

**Measurements:** The following parameters were measured to identify the location of MF:

- 1) Distance and diameter (Figure 1):
  - a. Vertical diameter (VD) = measured from the upper and lower edges of the MF.
  - b. Horizontal diameter (HD) = as the maximum transverse diameter of the foramen.
  - c. Distance A = distance between alveolar crest to upper margin of the mental foramen.
  - d. Distance B = distance between the lower margin of the mental foramen to the lower border of the mandible.
- 2) Position: To locate the horizontal position of MF, five locations were analyzed (the position of the MF was recorded as lying in line with the long axis of a tooth or interdental space) [11] (Figure 1d).
  - P1= below the first premolar.
  - P2= between the first and second premolar.
  - P3= below the second premolar.
  - P4= between the second premolar and first molar.
  - P5= below the first molar.



**Figure 1.** (a) CBCT shows the measurement of the vertical diameter of the MF, (b) the horizontal diameter of the MF (c) the Distance from MF to the alveolar margin & from MF to the lower border of the mandible (d) Position of MF.

### 2.3. Statistical analysis

The collected data were processed, computed, and analyzed using SPSS software version 26. The horizontal and vertical diameter of the MF and distance to the mandible border were evaluated as the main outcome. Comparisons among genders and differences between the right and left sides were evaluated and results were considered significant when P-value was less than 0.05.

### 2.4. Compliance with ethical standards

All procedures performed in studies involving human participants were in accordance with the ethical standards of the research ethics committee in Benghazi-Libya. due to the retrospective nature of this study, formal consent is not required.

### 2.5. Study period

The study will be conducted in a 5-month period, from October 2023 to February 2024.

## 3. Results

For all subjects, the mean horizontal diameter was  $3.45 \pm 1.08$  mm and the mean vertical diameter was  $3.15 \pm 0.78$  mm on the right side. On the left, these were  $3.85 \pm 1.27$  mm and  $3.46 \pm 0.86$  mm, respectively (Table 1). The left VD is longer compared to the right VD. Similarly, left HD was longer as compared to right HD, these differences were statistically significant,  $P < 0.005$ . Table 2 demonstrates that the right vertical diameter is longer among males compared to females' right VD ( $3.31 \pm 0.84$  vs  $3.01 \pm 0.69$ ). These differences were statistically significant,  $P = 0.05$ . Similarly, left VD is longer among males compared to females' left VD ( $3.73 \pm 0.85$  vs  $3.23 \pm 0.81$ ). These differences were statistically significant,  $P < 0.005$ . Regarding the HD, the right-sided male measurements were longer as compared to right-sided female measurements, ( $3.59 \pm 1.11$  vs  $3.33 \pm 1.05$ ). These differences were not statistically significant,  $P > 0.05$ . The left-sided HD was longer in males as compared to left-sided female measurements, ( $4.21 \pm 1.49$  vs  $3.52 \pm 0.96$ ). These differences were statistically significant,  $P < 0.01$ . The average distance between MF and the alveolar margin of the mandible (Distance A) was  $13.77 \pm 2.42$  mm on the right side and  $13.57 \pm 2.21$  mm on the left side, with males slightly higher than females. While the distance between MF and the lower border of the mandible (Distance B) was  $12.63 \pm 1.72$  mm on the right side and  $12.23 \pm 1.68$  mm on the left side, with males exhibiting a greater distance than females. The average distance between MF and the alveolar margin of the mandible (Distance A) is longer on the right side compared to the left side distance ( $13.77 \pm 2.42$  vs  $13.57 \pm 2.21$ ). These differences were statistically significant,  $P < 0.001$ . Similarly, the distance between MF and the lower border of the mandible (Distance B) is longer on the right side compared to the left side distance ( $12.63 \pm 1.72$  vs  $12.23 \pm 1.68$ ). These differences were statistically significant,  $P < 0.001$  (Table 3). Table 4 demonstrates that the right-side distance between MF and the alveolar margin of the mandible (Distance A) is longer in males compared to females ( $13.97 \pm 2.23$  vs  $13.59 \pm 2.58$ ). These differences were not statistically significant,  $P > 0.05$ . Similarly, the left-sided measurements were not statistically significant between males & females. The distance between MF and the lower border of the mandible (Distance B) is longer on the males' right side compared to the female right-side distance ( $13.40 \pm 1.58$  vs

11.96±1.55). These differences were statistically significant, P<0.001. Similarly, the distance between MF and the lower border of the mandible (Distance B) is longer on the male's left side compared to the female left side distance (12.72±1.63 vs 11.81±1.63). These differences were statistically significant, P<0.01. In the present study, the most common position of the mental foramen relative to the lower teeth was position P3 was located below the second premolar in 52.8% of cases and was found to be in 26.4 % of the cases on the right side and 26.4 % on the left side, It was followed by the position P2 in line with the long axis between first and second premolars 24.5% of cases. and was 9.4 % and 15.1 % on the right side and left side respectively. No foramen was observed in P5 (below the first molar).

**Table 1.** Morphometric Measurements of Mental foramen (MF) between two sides in the same individual.

Measurement	Total		Right		Left	
	(mean±SD) mm	p value	(mean±SD) mm	(mean±SD) mm	(mean±SD) mm	p value
VD	6.62±1.42	0.000	3.15± 0.78	3.46±0.86	0.000	
HD	7.31±1.90		3.45±1.08	3.85±1.27	0.002	

VD = Vertical diameter. HD = Horizontal diameter

**Table 2.** Morphometric Measurements of Mental foramen (MF) on both sides relative to genders.

Measurement	Right side		p value	Left side		p value
	male	female		male	female	
VD (mean±SD)	3.31±.84	3.01±.69	0.05	3.73±0.85	3.23±0.81	.003
HD (mean±SD)	3.59±1.11	3.33±1.05	0.22	4.21±1.49	3.52±0.96	.005

**Table 3.** Location of the mental foramen of both sides in the same individual. (Distance of mental foramen from various parts of mandible)

Measurement	Right side (mean±SD)mm	Left side (mean±SD)mm	p value
Distance between MF and alveolar margin of mandible (Distance A)	13.77±2.42	13.57±2.21	.000
Distance between MF and lower border of mandible (Distance B)	12.63±1.72	12.23±1.68	.000

**Table 4.** Location of mental foramen on both sides relative to genders. (Distance of mental foramen from various parts of mandible) between genders

Measurement	Right side (mean±SD)mm		p value	Left side (mean±SD)mm		p value
	male	female		male	female	
Distance between MF and alveolar	13.97±2.23	13.59±2.58	0.427	13.84±2.51	13.33±1.90	0.237

margin of mandible (Distance A)						
Distance between MF and lower border of mandible (Distance B)	13.40±1.58	11.96±1.55	0.000	12.72±1.63	11.81±1.63	0.006

**Table 5:** Frequency of the position of the mental foramen of both sides in the same individual in relation to lower teeth.

Position	Right side%	Left side%	
P1	0	3	3
P2	20	32	52
P3	56	56	112
P4	30	15	45
P5	0	0	0

The most prevalent position was P3 in the case of left and right-side mental foramen.

P1 =below the first premolar; P2 = between the first and second premolar; P3 = below the second premolar; P4 = between the second premolar and first molar; P5 = below the first molar.

**Table 6:** The difference in the right mental foramen (MF) position in relation to lower teeth in different genders.

Gender	Position (right side)					Total
	P1	P2	P3	P4	P5	
Male	0	9	27	13	0	49
Female	0	11	29	17	0	57
Total	0	20	56	30	0	106

P1 =below the first premolar; P2 = between the first and second premolar; P3= below the second premolar; P4= between the second premolar and first molar; P5 = below the first molar.

**Table 7:** The difference in left mental foramen (MF) position in relation to lower teeth in different genders.

Gender	Position (left side)					Total
	P1	P2	P3	P4	P5	
Male	2	17	22	8	0	49
Female	1	15	34	7	0	57
Total	3	32	56	15	0	106

P1 =below the first premolar; P2 = between the first and second premolar; P3= below the second premolar; P4= between the second premolar and first molar; P5 = below the first molar.

#### 4. Discussion

When performing surgical procedures on the mandible, such as curettage of the premolars, fillings procedures, dental implants, root canal treatments, orthognathic surgeries, pre-prosthetic surgeries, and flap operations of the lower teeth region, a dental surgeon must accurately identify and locate the MF [12, 13]. According to our study, the most commonly present position of the MF as related to the lower set of teeth was P3 (52.8%) 'below the 2nd premolar' (26.4%) on the right and (26.4%) on the left side of the mandible. The next common position was P2 i.e., between the premolars. These results were consistent with those of Parmar A et al [7], Wang et al [14], Apinhasmit et al [15] & Singh R [16]. Parmar A et al [7] showed the most common position to be P3 in 64.7% of cases on the right and 66.7% of cases on the left sides. This position (P3) has been demonstrated to be prevalent in several other studies, including 52.94% of Sri Lankan cases [17], 44.08% (right), and 46.23% (left) in western Indian cases [18], 55.7% (right) and 61.4% (left) in Turkish cases [11], 45% cases in Tanzanian cases [19], 64.3% cases in Korean cases [20], and 69.2% cases in Malay populations [21]. Numerous researches have evaluated the position of MF in Arabic populations including those in Saudi Arabia [22-26], Egypt [27], and Morocco [28]. According to the findings, In the Kingdom of Saudi Arabia, five previous studies investigated the position of the MF using CBCT. As Mashyakhy et al [22], used CBCT to locate the MF, they discovered that in 56.9% of cases, the MF was under the mandibular second premolar, and in 26.9% of cases, it was between the first and second mandibular premolar. Using CBCT, Al Mahalawy et al [23], discovered that in 52.8% of the patients in the eastern part of Saudi Arabia, the MF was located below the mandibular second premolar, whereas in 29.6% of the subjects, it was located between the premolars. Moreover, Aldosimani et al [24] found that the MF was located adjacent to the mandibular second premolar in about 68.1% of the patients in the Kingdom's central region.

Furthermore, it has been shown by Mahabob et al. [25] and Srivastava [26] that MFs are situated in the eastern and northern regions, respectively, below the second premolars. Those studies were in agreement with the findings of our study. Our findings were similar to those of Alam et al. [27], who investigated the Saudi, Egyptian, and Jordanian populations and concluded that the majority of them presented the MF under the long axis of the second mandibular premolar. In another study in Morocco by Chkoura et al [28], using panoramic radiographs, the mental foramen was located just below the apex of the second premolar in 62.7% of the patients and between the first and second premolars in 30%. The study conducted by Haghanifar and Rokouei [29], in their radiographic analysis of the MF, found that 47.2% of cases of the MF were found to be between the two premolars (P2). According to a different Turkish study [30], 71.5% of the patients showed that the MF was most frequently located between the two premolars (P2). Also, Rai R et al [31] reported that the most common position was between the 2nd premolar and 1st molar on the right (P4 65%) and between 1st and 2nd premolars on the left side (P2 40%). The position of the

MF varies among ethnic groups [32]. The mean vertical diameters (VD) of the MF were  $3.15\pm 0.78\text{mm}$  and  $3.46\pm 0.86\text{mm}$  on the right and left sides, respectively, while the mean horizontal diameters (HD) were  $3.45\pm 1.08\text{mm}$  and  $3.85\pm 1.27\text{mm}$  on the right and left sides. Our results were much higher than that of Rai R et al [31], who reported mean HD of MF of  $2.63\pm 0.85\text{mm}$  and  $2.61\pm 0.85\text{mm}$  on the right and left sides, respectively, while the mean (VD) was  $2.29\pm 0.60\text{mm}$  and  $2.33\pm 0.64\text{mm}$  on the right and left sides. On the other hand, a study by Rastogi R et al [33] reported mean VD of  $3.58\pm 0.17\text{mm}$  and  $3.55\pm 0.18\text{mm}$  on the right and left sides, respectively, and mean HD of  $4.57\pm 0.19\text{mm}$  on the right and  $4.61\pm 0.17$  on the left. Ogus et al [34]. reported that the mean HD was 2.93 mm (right) and 3.14 mm (left), whereas the mean VD was 2.31 mm (right) and 2.64 mm (left). In their sample, there was a significant difference between HD and VD, this may indicate a more oval-shaped MF. Additionally, we measured the mean distance (Distance A) between the alveolar crest and the upper margin of MF, which was  $13.77\pm 2.42$  mm on the right and  $13.57\pm 2.21$  mm on the left. and the average distance between the lower border of the mandible and the lower margin of the MF (Distance B) was  $12.63\pm 1.72$  mm on the right and  $12.23\pm 1.68$  mm on the left similar to the findings of Rai R et al. were the mean (Distance BB) was 12.43 mm and 12.17 mm. Our results were much higher than that of Siddiqui et al [18], (mean Distance A was 10.2mm (right) and 10mm (left) whereas Distance B was 9.9mm and 10.1mm respectively) and Parmar A. et al [7] Distance A was 10.6mm (right) and 10.3mm (left) whereas Distance B was 10.7mm on both the sides.

## 5. Conclusion:

The MF was most prevalent below the level of the second mandibular premolar, many papers highlight the importance of understanding the anatomical variations of the MF in dental procedures, such as implant placement and surgical interventions in the premolar region, to minimize the risk of complications and ensure successful outcomes.

## Limitations

The present study did not investigate the presence of accessory mental foramina, which could be significant in surgical procedures. Additionally, the relatively small sample sizes may restrict the generalizability of the results.

## Future plan

Further studies could investigate the relationship between the MF and other anatomical structures, such as accessory mental foramen, mandibular canal, and surrounding bone, to provide a more comprehensive understanding of its anatomical characteristics, especially in different age groups.

## Acknowledgment

We are deeply grateful to Ms. Heba ELdresi & Ms. Zainab Mhd, radiologist technicians who performed the morphometric analysis.

## References

1. Snell, R.S., Clinical anatomy for medical students. 2000: Lippincott Williams & Wilkins.
1. Chummy, S., Last's: Regional and applied. 2006, Churchill Livingstone Elsevier Limited.
2. Shankland 2nd, W., The position of the mental foramen in Asian Indians. The Journal of oral implantology, 1994. 20(2): p. 118-123.
3. Kumar, V., et al., Radiographic localization of mental foramen in Northeast and South Indian ethnic groups of Indian population. J Contemp Dent Pract, 2014. 15(6): p. 766-9.
4. Chandra, A., et al., Determination of sex by radiographic analysis of mental foramen in North Indian population. Journal of forensic dental sciences, 2013. 5(1): p. 52.
5. Eboh, D.E., Analysis of mental foramen in dry human mandibles of adult Nigerians. African journal of medicine and medical sciences, 2014. 43(2): p. 107-113.
6. Parmar, A., et al., Morphological and morphometric analysis of mental foramen in dry human mandibles. Int J Med Sci Public Health, 2013. 2(3): p. 640-644.
7. Aminoshariae, A., A. Su, and J.C. Kulild, Determination of the location of the mental foramen: a critical review. Journal of endodontics, 2014. 40(4): p. 471-475.
8. Vujanovic-Eskenazi, A., et al., A retrospective radiographic evaluation of the anterior loop of the mental nerve: comparison between panoramic radiography and cone beam computerized tomography. Medicina oral, patologia oral y cirugia bucal, 2015. 20(2): p. e239.
9. Scarfe, W.C. and A.G. Farman, What is cone-beam CT and how does it work? Dental Clinics of North America, 2008. 52(4): p. 707-730.
10. Yesilyurt, H., et al., Local differences of the position of the mental foramen. Folia morphologica, 2008. 67(1): p. 32-35.
11. Nkenke, E., et al., Morbidity of harvesting of chin grafts: a prospective study. Clinical oral implants research, 2001. 12(5): p. 495-502.
12. Sbordone, L., et al., Clinical survey of neurosensory side-effects of mandibular parasymphiseal bone harvesting. International journal of oral and maxillofacial surgery, 2009. 38(2): p. 139-145.
13. Wang, T.-M., et al., A clinical and anatomical study of the location of the mental foramen in adult Chinese mandibles. Cells Tissues Organs, 1986. 126(1): p. 29-33.
14. Apinhasmit, W., et al., Mental foramen in Thais: an anatomical variation related to gender and side. Surgical and Radiologic Anatomy, 2006. 28: p. 529-533.
15. Singh, R. and A.K. Srivastav, Evaluation of position, shape, size and incidence of mental foramen and accessory mental foramen in Indian adult human skulls. Anatomy, 2011. 5(1): p. 23-29.
16. Ilayperuma, I., G. Nanayakkara, and N. Palahepitiya, Morphometric analysis of the mental foramen in adult Sri Lankan mandibles. Int J Morphol, 2009. 27(4): p. 1019-24.
17. Siddiqui, A.U., et al., Morphological and morphometric analysis of mental foramen utilizing various assessment parameters in dry human mandibles. Int J Stud Res, 2011. 1(1): p. 19-22.
18. Fabian, F.M., Position, shape and direction of opening of the mental foramen in dry mandibles of Tanzanian adult black males. Italian journal of anatomy and embryology= Archivio italiano di anatomia ed embriologia, 2007. 112(3): p. 169-177.
19. Kim, I.-S., et al., Position of the mental foramen in a Korean population: a clinical and radiographic study. Implant dentistry, 2006. 15(4): p. 404-411.

20. Ngeow, W.C. and Y. Yuzawati, The location of the mental foramen in a selected Malay population. *Journal of oral science*, 2003. 45(3): p. 171-175.
21. Mashyakhy, M., et al., Structural features of the mental foramen in a saudi subpopulation: a retrospective CBCT study. *BioMed Research International*, 2021. 2021.
22. Al-Mahalawy, H., et al., Determination of the position of mental foramen and frequency of anterior loop in Saudi population. A retrospective CBCT study. *The Saudi Dental Journal*, 2017. 29(1): p. 29-35.
23. Aldosimani, M.A., et al., Analysis of mandibular premolar root position in relation to adjacent cortical plates and mental foramen using cone beam computed tomography in the Saudi population. *Saudi Medical Journal*, 2019. 40(3): p. 298.
24. Mahabob, M.N., et al., Assessment of the mental foramen location in a sample of Saudi Al Hasa, population using cone-beam computed tomography technology: A retrospective study. *Journal of Oral Research*, 2021. 10(3): p. 1-9.
25. Srivastava, K.C., A CBCT aided assessment for the location of mental foramen and the emergence pattern of mental nerve in different dentition status of the Saudi Arabian population. *Brazilian dental Science*, 2021. 24(1): p. 10 P-10 P.
26. Alam, M.K., et al., 3D CBCT morphometric assessment of mental foramen in Arabic population and global comparison: imperative for invasive and non-invasive procedures in mandible. *Acta Odontologica Scandinavica*, 2018. 76(2): p. 98-104.
27. Chkoura, A. and W. El Wady, Position of the mental foramen in a Moroccan population: A radiographic study. *Imaging science in dentistry*, 2013. 43(2): p. 71-75.
28. Haghaniifar, S. and M. Rokouei, Radiographic evaluation of the mental foramen in a selected Iranian population. *Indian Journal of dental research*, 2009. 20(2): p. 150-152.
29. Gungor, K., et al., A radiographic study of location of mental foramen in a selected Turkish population on panoramic radiograph. *Collegium antropologicum*, 2006. 30(4): p. 801-805.
30. Rai, R., S. Shrestha, and S. Jha, Mental foramen: a morphological and morphometrical study. *Int J Health Biomed Res*, 2014. 2: p. 144-150.
31. Sawyer, D.R., M.L. Kiely, and M.A. Pyle, The frequency of accessory mental foramina in four ethnic groups. *Archives of oral biology*, 1998. 43(5): p. 417-420.
32. Rastogi, R., et al., Morphology and morphometry of the mental foramen in dry adult human mandibles from central India and their clinical correlation. *Eur J Anat*, 2012. 16(1): p. 22-26.
33. Oguz, O. and M. Bozkir, Evaluation of location of mandibular and mental foramina in dry, young, adult human male, dentulous mandibles. *The West Indian Medical Journal*, 2002. 51(1): p. 14-16.