



International Congress on Biological, Physical And Chemical Studies

International Congress on Biological, Physical And Chemical Studies - is an international conference platform under open access policy. The conference is led by international expert members who take an objective approach to peer review, ensuring each research paper is reviewed, edited by authors and evaluated on its own scholarly merits and research integration. Publishing and joining on the proceeding of the International Congress on Biological, Physical And Chemical Studies will ensure publishing experience and indexing possibilities on various global indexing.

Pathomorphological Changes in Birds Affected by Pullorosis and Streptococcosis

Kiyamova Z. N.

Independent researcher, Scientific Research Institute of Veterinary
Medicine of Uzbekistan

ABSTRACT

The article describes the compatibility and pathomorphological changes of pullorosis and streptococcal diseases of birds. Information about pathological changes in the body of birds and their differential diagnosis is provided.

KEYWORDS: chickens, bacteria, pathogens, pullorosis, streptococcosis, pathomorphological changes, bacteriology, yellow peritonitis, diagnosis, dystrophy, necrotic processes, inflammation.

The relevance of the topic. The coexistence of infectious streptococcal and pullorosis diseases in poultry, especially in chickens, is one of the challenges facing veterinary science and practice. Because they are much more difficult to diagnose, pathoanatomical studies of slaughtered or dead birds reveal the signs and changes in their appearance and internal organs characteristic of the disease. This, in turn, creates serious difficulties in making an accurate diagnosis of the disease. One of the current issues is the development of pathomorphological diagnostics of streptococcal and pullorosis diseases in poultry for accurate diagnosis.

For the development of poultry farming, it is necessary to create and implement new measures to effectively combat infectious diseases among chickens. One of the most important tasks facing veterinary science is the development, improvement and implementation of measures for the diagnosis, prevention and control of infectious diseases that occur in poultry, especially chickens, and cause great economic damage.

The purpose of the study. It consists in the study of pathomorphological changes in the internal organs of birds infected with pullorosis and streptococcosis in vivo.

Clinical signs. Clinical signs of the disease, depending on the direction of transmission, the incubation period can range from a day to a week. At the same time, poultry exhibits very complex, specific clinical signs of each disease. For example, in the acute course, lethargy, drowsiness, increased breathing, general weakness, loss of appetite, nervous conditions, catarrhal-purulent or fibrinous conjunctivitis, clouding of the cornea of the eye, diarrhea are observed. The droppings are white, in some cases greenish-gray, and the smell is extremely unpleasant. The

mortality rate is 70-80%. With a mixed course of diseases, lameness, swelling of the joints, and signs of lung damage in chickens are sometimes noted.

The results of the study. Research work was carried out during 2024 at the “Kattakurgan-Bird” farms Kattakurgan district of the Samarkand region, “Afrasiab-Bird” farms in the city of Samarkand and birds brought from farms to the vivarium of the “Microbiology” laboratory of the Scientific Research Institute of Veterinary Medicine.

Dispensary inspections of egg-type chickens for more than 3,500 heads were carried out in these poultry farms.

As a result of the conducted clinical studies, pathomorphological examination of the internal organs of birds that died in vivo from pullorosis and streptococcosis revealed pathomorphological changes depending on the age of chickens and the form of manifestation of the disease. With pullorosis of chickens, hemodynamic disorders were observed in the liver, kidneys and heart, degenerative changes and necrosis followed by the formation of granulomas, hyperemia and edema in the lungs, catarrhal enteritis, additional cuticulitis, catarrhal fibrinous colitis, spleen hyperplasia, hyperemia, nerve endings in the brain, cellular degeneration has developed. Some chickens had lesions of the ovaries and oviducts, peritonitis, cloacitis, the presence of gray-white foci of necrosis, and the development of dystrophic changes.

In laboratory conditions, in order to study the histogram of pullorosis, samples of the organs of chicks who died from lesions and were forcibly slaughtered were taken for pathomorphological examination. For this purpose, the biopsy method was initially used for histological examination of samples in small quantities, fragments were taken from sick chickens from the following organs; samples were taken from the trachea, lymph node, liver, lungs, heart, spleen and kidneys, and pathological changes were examined histologically. Pathological samples were taken for bacteriological examination from the internal organs of all examined birds and planted on various nutrient media (Levin's agar, Ploskirieva, salmonella shigella and 5% bloody agar).

Incisions were extracted from the blocks using a microtome, a micro-preparation was made on the glass of the product, stained with hemotoxylin and eosin dye and microscoped. Microscopy revealed pathohistological changes that occurred in the internal organs of the bird.

For histological examination of pathological samples (fragments) from internal organs and tissues, a histopreparation was prepared using the paraffin method as follows (it was carried out in dark glass vials of 50-100 milliliters).

I. Fixation. 1. The obtained pathological samples (fragments) were kept in 10-12% formalin solution for 24 hours. 2. kept for 24 hours in a 96 °C solution of ethyl alcohol and formalin in equal proportions (1:1) ; 3. In absolute 96-100 °C alcohol, these particles were aged for 12-24 hours.

II. Dehydration. 1. The obtained pathological samples (fragments) were kept for 24 hours in a 96 °C alcohol solution for dehydration; 2. The next day, they were also soaked for another 24 hours in a 96 °C alcohol solution;

III. Put paraffin wax. 1. Soak in equal proportions in a solution of 96 °C alcohol and chloroform for 6-12 hours; 2. They were kept in a pure chloroform solution for 6-12 hours. At the end of storage, a lightening of the color of the pieces was observed; 3. For better uniform absorption of the paraffin, the pieces were placed in a solution of molten paraffin and chloroform in equal volume proportions and left for 2-3 hours in a thermostat with a temperature of +35 + 40 °C. Sometimes such solutions were taken out for storage in a hardened state when they were not in use; 4. The pieces were then placed in molten paraffin wax, which was stored in a thermostat at a temperature of +54 + 55 °C. In this case, the pieces were held in molten paraffin in the first container for 1.5-2.5 hours, and then, using heated tweezers, they were placed in the second container and held in this position for 0.5-1.5 hours, paying attention to the size and thickness of the lumps; 5. The pieces were placed in a jar, glycerin was applied to the bottom of which and

heated to +60+70 °C using a gas burner, and melted pure paraffin was placed on top to a coating 0.5 cm thick.; 6. A container of paraffin wax with pieces was cooled in a large container with cold water. In this case, the paraffin was cooled based on its melting when moving from bottom to top.; 7. When the paraffin hardened, it was cut off from the edges, this paraffin was necessarily in a homogeneous state, if it was found that there were limited areas of fluidity in the paraffin (which crumble when broken, set), it was released again with a new portion of paraffin; 8. Blocks were cut out of the hardened paraffin, leaving a layer of paraffin at least 2 mm thick around the fragments. At the same time, each piece was taken separately; 9. The resulting blocks were glued together with a spatula so that the edges of the heated blocks did not stick out of the baseboard with most of the paraffin.

Histological sections were made from the blocks using a microtome, and a micropreparation was prepared on the glass of the product, stained with hemotoxylin and eosin dye, and microscopied. Microscopy revealed pathohistological changes that occurred in the internal organs of the chicks.

According to the results of histological examination; during pathomorphological examination of the internal organs of chickens, the main changes most often occurred in the parenchymal organs. A particularly strong development of hemodynamic and dystrophic processes in their chicks was observed in the first 1-5 days of life.

The cardiovascular system is expanded, the cells of the vessel wall are clogged, the endothelium migrates, there are much more clusters of cells consisting of histiocytes, lymphoids and leukocytes around some vessels, muscles are differentiated into fibers, some fibers undergo granular dystrophy. The liver is enlarged, and necrotic lesions have been observed. (Figure No. 1).

Hemorrhagic necrosing pneumonia is strongly developed in the lungs. The cavities of most alveoli are filled with red blood cells. The interalveolar capillary networks expand and fill with blood, as a result of which the barriers also thicken and the connective tissue fibers fuse. It was found that as a result of these changes, a significant part of the lung parenchyma suffers from atelectasis. In comparative experiments, it was observed that interstitial tissue also swells in all parts of the lungs.

Changes in the larynx were expressed in the form of catarrhal or severe fibrinous – hemorrhagic and desquamative inflammations. Due to a strong outbreak of desquamation of the respiratory epithelium in birds of the first experimental group, the private layer of the mucous membranes was completely exposed and sharply swollen, as well as infiltrated by a large number of pseudo eosinophilic leukocytes. Lymphoid cells accumulate in separate vessels. It was found that the mucous membrane of some birds is partially necrotic and swollen.

A necrotic mass consisting of fibrin, fragments of the respiratory epithelium, pseudo eosinophils, lymphocytes, and erythrocytes was detected in the larynx.

Pathohistological changes in the spleen are expressed in overcrowding of blood vessels, less protrusion of trabeculae, indistinctness of the appearance of fibers. The red border of the pulp is expanded. In some places, small hemorrhages and lymphoid accumulations are visible. These changes are the result of a common pathohistological process occurring in the body.

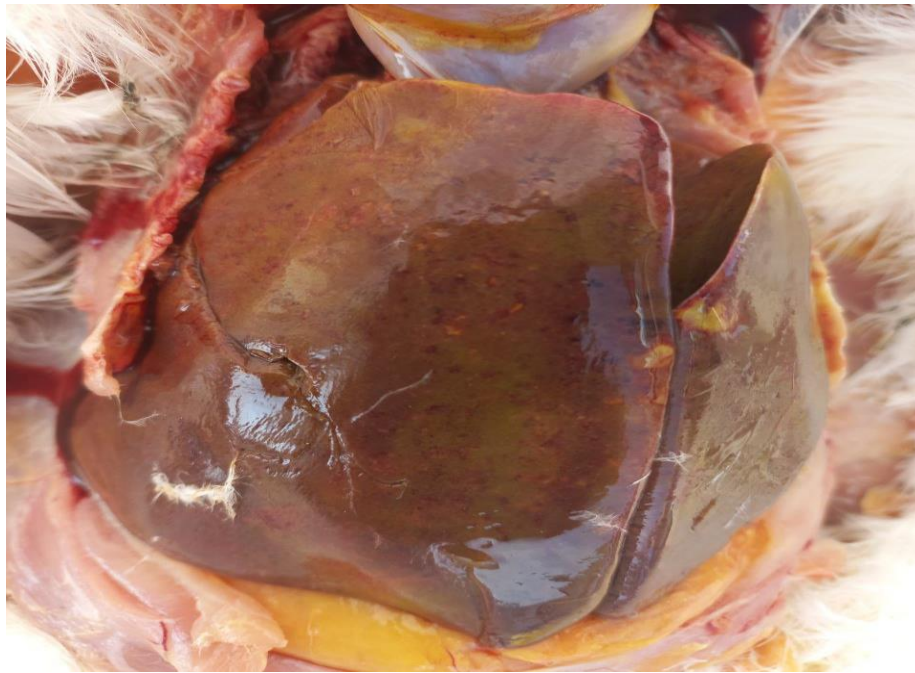


Figure 1. The liver is enlarged, the presence of necrotic foci was observed.

Histological changes in lymph nodes are not the same for all nodes. Noticeable changes occurred in the nodes of the portal, mesenteric and pulmonary intestinal walls, which developed serous edema, serous hemorrhagic lymphadenitis and extravasates of various sizes. Along with hemorrhages in the lymph nodes located near the parts of the lungs where severe pathological processes occur, the sinuses are filled with clusters of lymphocytes and leukocytes, adult birds have increased follicle sizes, and the number of lymphocytes is increased (Fig.2-3).

Pathohistological changes occurring in the kidneys were observed mainly in the form of general pathological processes, hemodynamic changes and granular, and sometimes fatty degeneration of the epithelium of the renal tubules were often detected. As a result of the expansion of the capillary meshes of the renal globules, only clusters of red blood cells were visible under the microscope. It was found that the capsules around the balls are enlarged, filled with pus and fibrin exudate. Dense and straight tubules arise as a result of an increase in the epithelium, the boundary of which is unknown. Epithelial nuclei undergo rexis as well as lysis. Morphological changes also occurred in the kidneys, and, like in other organs, irreversible processes were observed in this part.

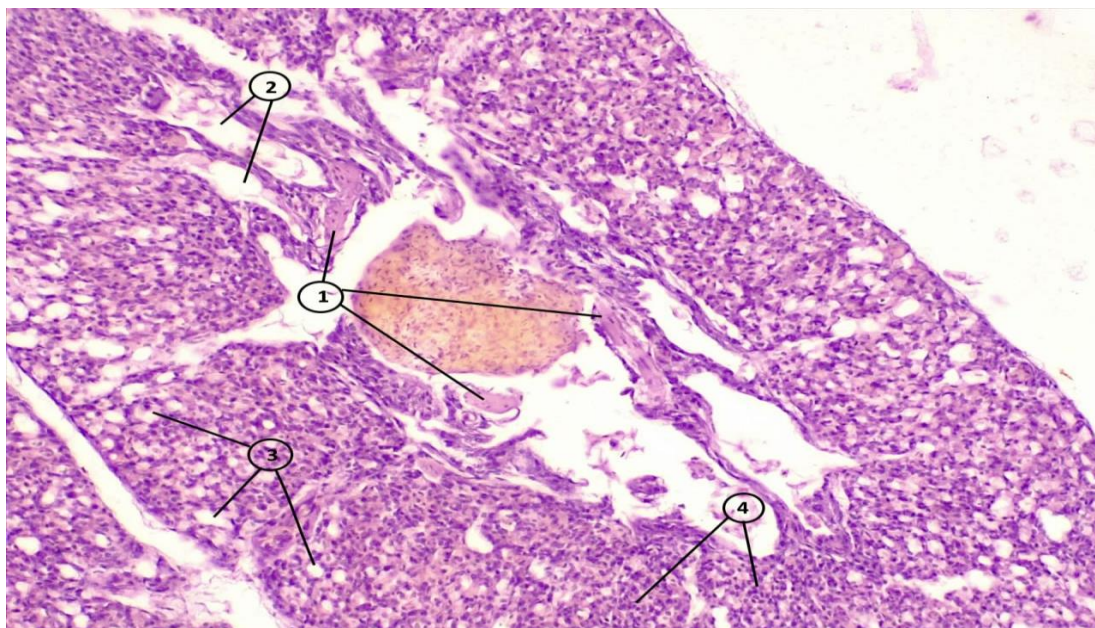


Figure 2. Serous hemorrhagic lymphadenitis and vascular congestion.

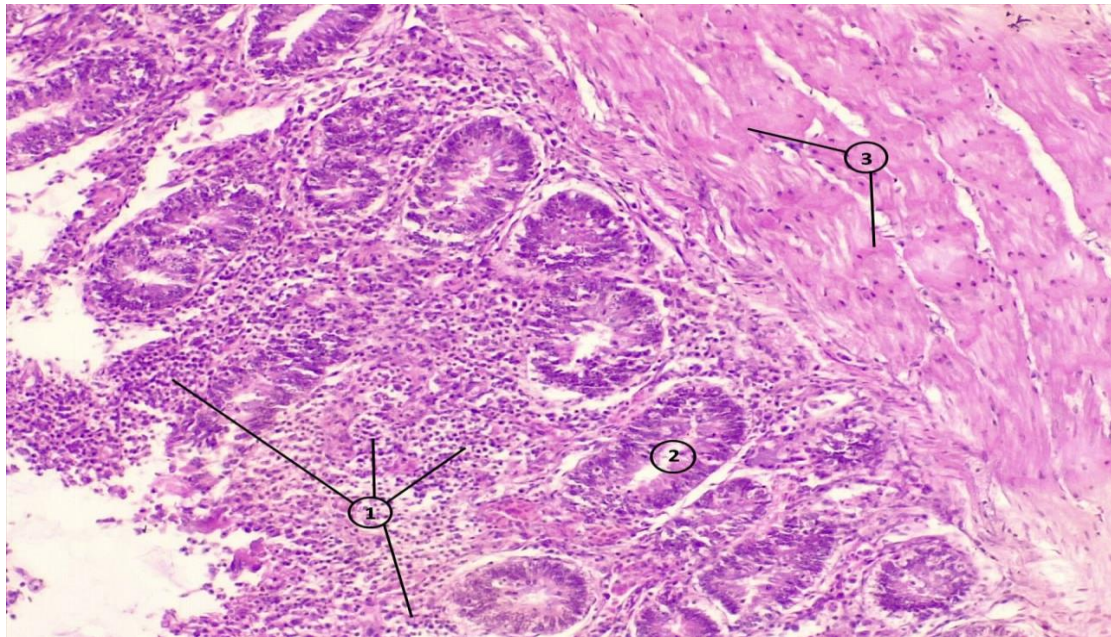


Figure 3. Filling of the intestine with purulent and fibrin exudate.

Conclusion. Studies have shown that the combined incidence of pullorosis and streptococcus in chickens occurs in 18-21% of the study area, and as a result of meeting in the same organism, they experience complex clinical and pathomorphological changes. The chicks revealed inflammation in the intestinal system, necrotic processes, stagnation of blood, as well as the presence of parathyroid hormone nodes in the liver, lungs, desquamate inflammation is characteristic of pullorosis, and the presence of degenerative, dystrophic, hemorrhages in the heart, spleen, lymph nodes in the kidneys, thinning of the walls of blood vessels-for streptococcus.

REFERENCES.

1. Bakulin V.A. Diseases of birds. St. Petersburg: Art of Russia, 2006. - 688 p.
2. Diseases of domestic and agricultural birds / B. U. Kelnek [et al.]; edited by B.W. Kelnek [et al.]; translated from English by I. Grigorev [and others]. Moscow: AQUARIUM BOOK, 2003. 1232 p.
3. Ablov A.M. Streptococcosis of mammals and birds and the species characteristics of pathogens in the Baikal region / A.M. Ablov, E.V. Anganov, A.C. Batomunkuyev // Izvestiya Irkutsk State University. Series: biology, ecology. – 2015.– Vol. 11. – pp. 105-110
4. Niyazov F.A., Durdiev S.K., Alimardanov A.S. A barrier to the spread of diseases // Agriculture of Uzbekistan. 2008. No. 6. P. 26.
5. Niyazov F.A., Ibodullaev F.I., Yusupov M.G. Pathomorphological changes in the body of chickens with pullorosis. // Veterinary Medicine, 2008. No. 7, p. 18.
6. Navruzov, N. I., Kiyamova, Z. N., & Elmurodov, B. A. (2024). PATHOMORPHOLOGICAL NEOPLASMS IN CHICKENS INFECTED WITH SALMONELLA PULLOROMELLINARIUM. *World scientific research journal*, 25(1), 141-151.
7. Elmurodov, B., Navruzov, N., & Kiyamova, Z. (2024). Pathomorphological changes in chickens infected with Salmonella pullorum Gallinarium. *in Library*, 1(1), 141-151.
8. Elmurodov, B., & Kiyamova, Z. (2022). The coexistence of respiratory mycoplasmosis and salmonellosis of poultry. *in Library*, 22(4), 10-10.